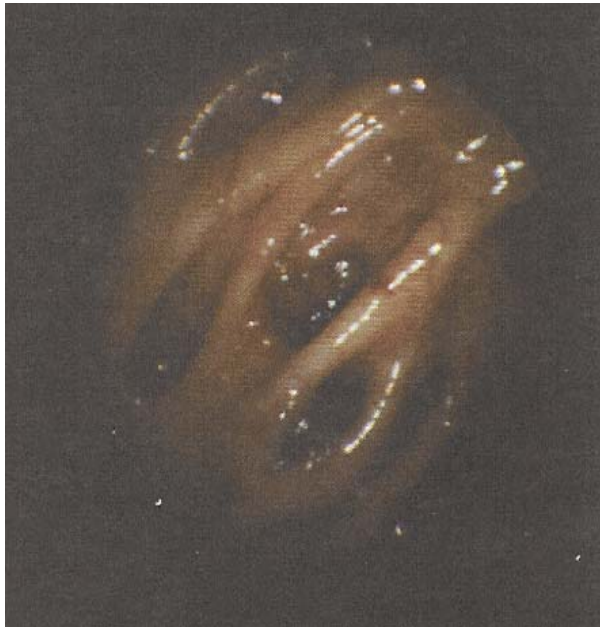
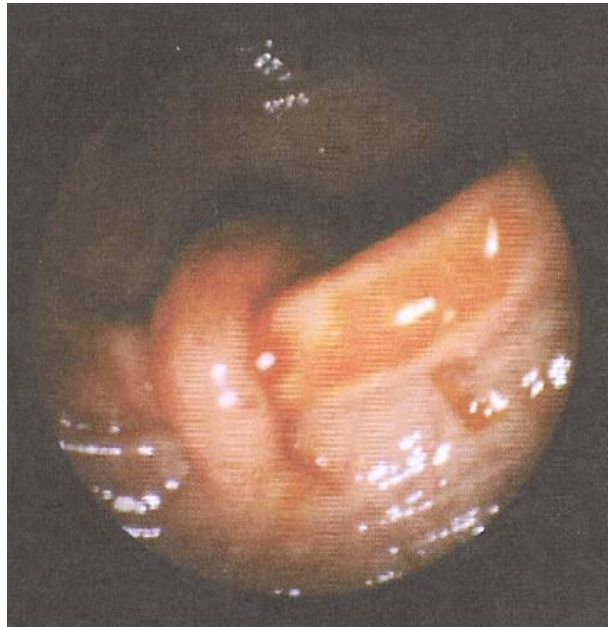
CONDITIONS THAT DEVELOP IN THE DIGESTIVE CANALS



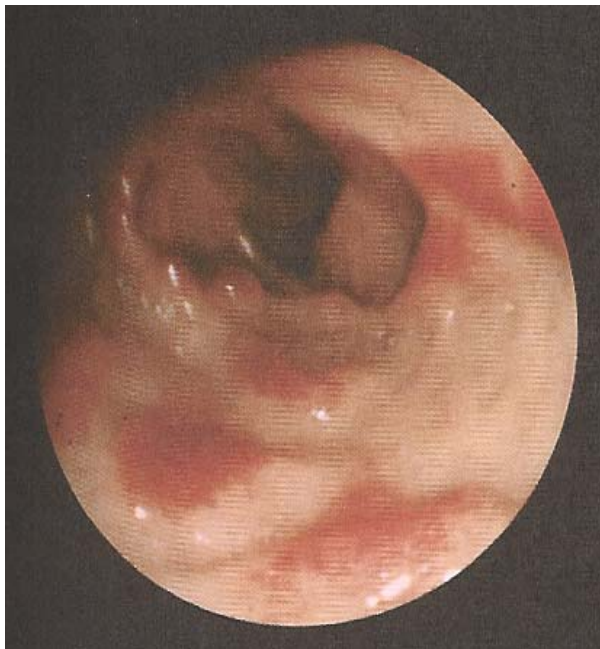5 Severe Diverticulitis

Here the center diverticulum is oozing a small amount of bright red blood, while the diverticulum beneath is filled with fecal pellets.



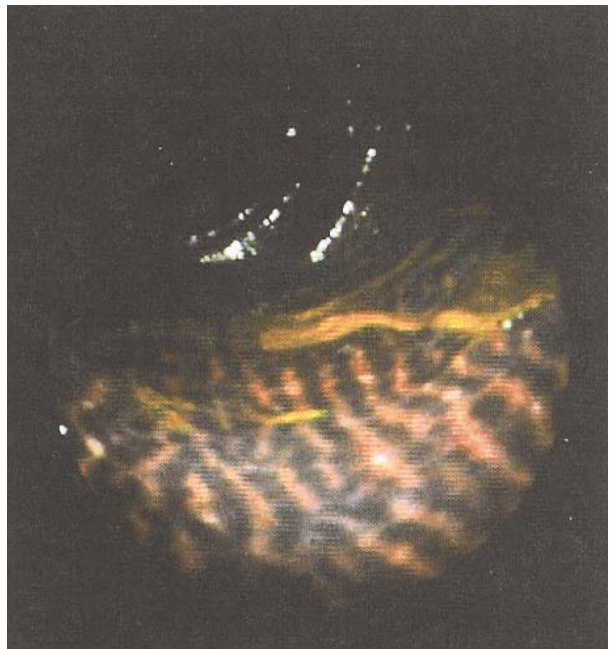
6 Polyp in the Sigmoid Colon

The long stalk of a sigmoid polyp is climbing over the mucosal fold. Polyps are another form of mucous plaque.



7 Chron's Iletis

The mucosa is thickened and ulcerated on the left side of the ileum (that portion of the small intestines just prior to the colon), while the right side is devoid of plaque.



8 Severe Melanosis Coli

Characteristic of this condition (melanin) are heavy deposits of dark pigment which impart a snake-like appearance to the mucosa of the ascending colon. The mucoid plaque can take various colors, as well as shapes and forms.